

## Olgu Sunumu

# Paradoxal Air Embolism Occuring During Sitting Position in a Patient Without an Intracardiac Defect

Kazım KARAASLAN\*, Erdoğan ÖZTÜRK\*, Ufuk TOPUZ\*, Asım ESEN\*

### ABSTRACT

*Sitting position is widely used in neurosurgery. One disadvantage of this position is a negative pressure in cranial veins in the sitting position that leads to air embolism. The most common cause is intracardiac shunting induced by patent foramen ovale, and it can be determined by transesophageal echocardiography (TEE). However, rarely, paradoxical air embolism (PAE) can occur through intrapulmonary functional arteriovenous anastomoses developing during anesthesia.*

*The aim of this paper is to increase awareness about development of PAE which can occur through intrapulmonary shunt aggravated by hypoxia in cases with high incidences of VAE (venous air embolism).*

**Keywords:** sitting position, paradoxal air embolism, hypoxia

### ÖZ

**İntrakardiyak Defekt Olmayan Olguda Oturur Pozisyonda Paradoksal Hava Embolisi**

*Oturur pozisyon nörocerrahide yaygın olarak kullanılmaktadır. Bu pozisyon dezavantajlarından biri intrakranial venlerdeki negatif basınç dolayısı ile oluşan hava embolisidir. En sık neden patent foramen ovale kaynaklı intrakardiyak şantlar olup transözofageal ekokardiyografi (TÖE) ile saptanabilmektedir. Ancak ender olarak anestezi sırasında, intrapulmoner fonksiyonel arteriyovenöz anastomozlar yoluyla paradoksal hava embolisi (PHE) olabilmektedir.*

*Bu makalenin amacı, VHE (venöz hava embolisi) insidansının yüksek olduğu olgularda hipoksinin agreeve ettiği PHE gelişebileceği konusunda farkındalık arttırmaktır.*

**Anahtar kelimeler:** oturur pozisyon, paradoksal hava embolisi, hipoksi

## INTRODUCTION

Studies performed on the cadavers of the previously healthy people showed the presence of intrapulmonary arteriovenous pathway (IPAV) with an internal diameter up to 0.5 mm these physiological transpulmonary arteriovenous pathways which are subclinical in many cases can be potentially identified in 90% of the individuals under hyperdynamic conditions (ie. during exercise). In recent studies, it has been suggested that IPAV shunts induce regulation of oxygen tension both in hypoxic and hyperoxic conditions<sup>[1]</sup>. The presence of these potential pathways makes

us consider continuous monitoring with TEE during surgeries performed especially on patients in the sitting position where high risk of venous air embolism (VAE) is expected.

The aims of this case presentation are both to increase awareness about development of PAE which can occur through intrapulmonary shunt aggravated by hypoxia in cases with higher VAE incidence and also encourage neuroanesthesiologists to routinely perform continuous TEE monitorisation.

## CASE REPORT

A 63-year-old male was scheduled for resection of the tumour at the cerebellopontine angle, and the operation was to be performed with the patient in the sitting position. In the preoperative evaluation, his medical story was not remarkable except for the bladder tumour surgery performed 6 months ago which was

**Alındığı tarih:** 06.05.2015

**Kabul tarihi:** 27.05.2015

\* Bezmialem Vakıf Üniversitesi Tıp Fakültesi, Anesteziyoloji ve Reanimasyon Anabilim Dalı

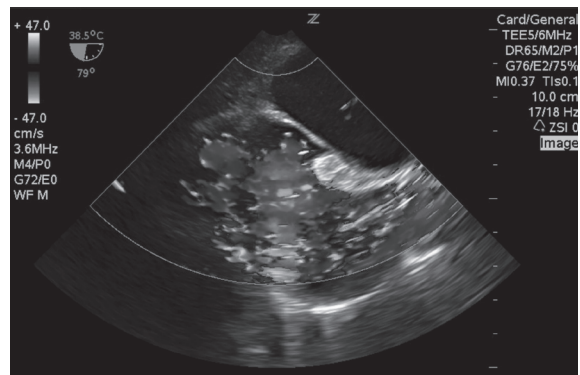
**Yazışma adresi:** Yrd. Doç. Dr. Asım Esen, Bezmialem Vakıf Üniversitesi Hastanesi, Anesteziyoloji ve Reanimasyon Anabilim Dalı, Vatan Cad. 34093 Fatih / İstanbul

**e-mail:** asimesen@mynet.com

completed without any problem. All laboratory test results were in normal ranges. Transcranial Doppler examination and colour duplex sonography revealed any abnormality of the carotid arteries. In the operating room, in addition to standard monitors used for invasive arterial blood pressure measurements, continuous central venous pressure was measured via right subclavian vein catheter, five-channel ECG and TEE.

The patient received 10 mL/kg of a NaCl 0.9% solution 30 min prior to the induction of anesthesia. After placement of routine monitors (continuous heart rate measurement, HR; non-invasive blood pressure, NIBP; pulse oximetry, SaO<sub>2</sub>; invasive arterial blood pressure, IBP; end-tidal carbon dioxide, EtCO<sub>2</sub>; central venous pressure, CVP) (Datex Ohmeda - Avance), anesthesia was induced with propofol (2 mg kg<sup>-1</sup>), and fentanyl (1.5 µg kg<sup>-1</sup>). Muscle relaxation was achieved with vecuronium (0.1 mg kg<sup>-1</sup>) followed by its infusion at a rate of 0.1 mg kg<sup>-1</sup> h<sup>-1</sup>. The trachea was intubated and lungs were ventilated with a mixture of oxygen and air (FiO<sub>2</sub> of 0.4-0.5). Minute ventilation was continuously adjusted to maintain an arterial carbon dioxide pressure (PaCO<sub>2</sub>) of 30-35 mmHg by serial arterial blood gas measurements. Anesthesia was then maintained with a propofol dose of 12 mg kg<sup>-1</sup> h<sup>-1</sup> which was reduced to 6 mg kg<sup>-1</sup> h<sup>-1</sup> after the first hour of anesthesia. Besides remifentanyl infusions (continuous infusion at a dose of 0.2-2 mcg kg<sup>-1</sup> min<sup>-1</sup> which was reduced to 0.1-1 mcg kg<sup>-1</sup> min<sup>-1</sup> after opening dura mater) were administered. Vecuronium administration was terminated 30 minutes before the end of the operation.

Neck and head of the patient were positioned with special care by using a Mayfield® clamp. Central venous line was positioned at 21 cm away from the superior vena cava-right atrial junction which was confirmed by TEE. Preoperatively, TEE Zonare® (P8-3TEE Phased Array, Zonare Medical System, Mountain View, CA, USA) probe was inserted after induction of anesthesia. There was no evidence of patent foramen ovale, atrial septal defect or ventricular septal defect in TEE obtained both with the patient in the supine and sitting positions (Figure 1). After induction of anesthesia (T0) with the patient in the supine position, results of the initial blood gas analysis were as follows: PaO<sub>2</sub> = 243 mmHg, fraction of inspired oxygen (FiO<sub>2</sub>) = 0.62%, and PaCO<sub>2</sub> = 32.3 mmHg. The patient was brought into sitting position shortly after.

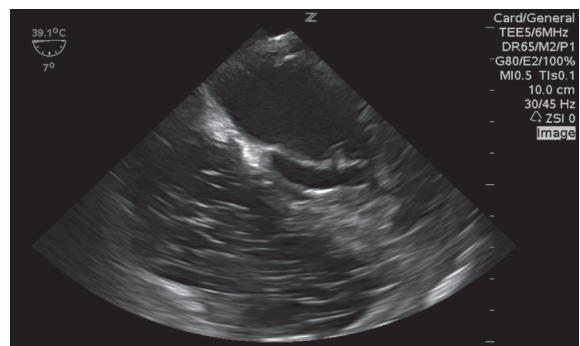

**Figure 1. The bicaval TEE view during operation. There is no PFO.**

PFO: Patent Foramen ovale  
TEE: Transesophageal ecocardiography

pressure controlled mode was employed for mechanical ventilation with the anesthesia machine, (Avans® GE Healthcare, Milwaukee, WI, USA). PEEP was not used in any time.

Massive VAE in the right heart was observed in the midesophageal four-chamber view on the TEE monitor screen at the 75 th. minute of the operation during tumor resection (Figure 2). Sudden decrease in blood pressure (from 125/48 to 81/50 mmHg) and hypocapnia [end-tidal CO<sub>2</sub> (EtCO<sub>2</sub>) values decreased from 33 to 21 mmHg] accompanied the manifestations. Rapid colloid infusion was performed through a peripheral large vein, and noradrenaline (0.03-0.5 µg kg<sup>-1</sup>min<sup>-1</sup>) was infused through the central catheter and 100% O<sub>2</sub> was used. During this period repeated manual jugular vein compressions were applied and possible extra-surgical causes of air leakage from central and peripheral venous lines were excluded. Mild acidosis and hypercapnia were observed in the arterial blood



**Figure 2. The four chamber TEE view. Common air bubbles in right heart after first VAE.**

VAE: Venous air embolism

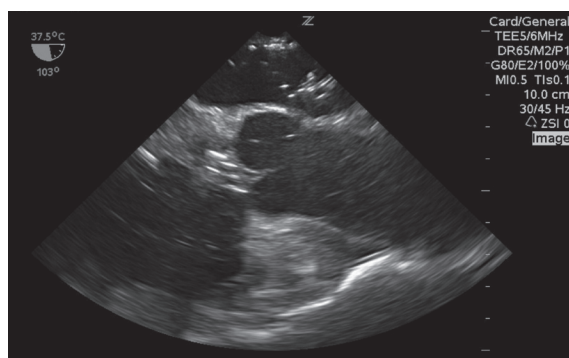
**Table 1. Arterial blood gas analyses of patient.**

	T <sub>0</sub>	T <sub>1</sub>	T <sub>2</sub>	T <sub>3</sub>	T <sub>4</sub>	T <sub>5</sub>
pH	7.38	7.29	7.26	7.14	7.24	7.27
PaO <sub>2</sub> (mmHg)	243	273	61.3	63.9	236	261
PaCO <sub>2</sub> (mmHg)	32.3	48.3	47	78	52.1	49.9
EtCO <sub>2</sub> (mmHg)	36	21	19	26	29	33
HCO <sub>3</sub> act (mmol/L)	26.1	23	21.6	26.3	19.8	22.1
BE (mmol/L)	-0.8	-3.5	-4.9	-3.3	-5.6	-5.2
% O <sub>2</sub> Sat	99.3	99.6	93.9	91.7	99.7	99.5
Na (mmol/L)	135	134	130	130.2	136	132
K (mmol/L)	3.28	3.25	3.88	3.86	3.87	3.95
Ca (mmol/L)	0.95	0.96	0.96	10.1	10.2	10.5
Glucose (mg/dl)	95	88	96	140	194	219
Lactat (mmol/L)	1.02	1.77	1.82	1.88	2.32	3.26

T<sub>0</sub>: After induction, T<sub>1</sub>: The first air embolism during operation, T<sub>2</sub>: The second air embolism during operation, T<sub>3</sub>: Observed air bubbles into the left heart, T<sub>4</sub>: After the air was aspirated through central catheter, T<sub>5</sub>: Arrival in the ICU.  
ICU: Intensive care unit

gas (T1) (Table 1). After aspiration of approximately 50 mL air through central venous catheter, any air bubble was not observed on TEE monitor screen and surgery was kept on. When stable hemodynamic state was ensured, inotropic drug infusion was stopped.

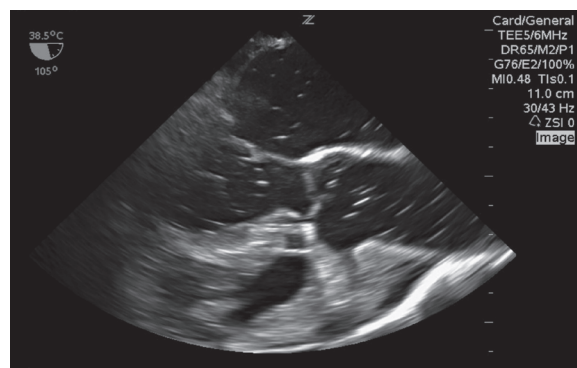
The second VAE at the TEE was observed at the 185. minute of the operation. For the arterial blood gas test, blood sample was taken immediately (T2). The second VAE led to a drop in EtCO<sub>2</sub> down to 19 mmHg. At this point, PaCO<sub>2</sub> increased from 32 to 47 mmHg. PaO<sub>2</sub> decreased from 243 to 61.3 mmHg, while FiO<sub>2</sub> remained constant at 0.75. The patient's blood pressure decreased to 75/43 mmHg while heart rate increased from 78 to 101 bpm. At this point, nor-epinephrine at an infusion rate of 0.03-0.5 µg kg<sup>-1</sup> min<sup>-1</sup> was required to achieve hemodynamic stability. Given this new hemodynamic instability, the surgical wound was closed with Surgicel® and the skull inci-



**Figure 3. The long axis TEE view after PAE. Air bubbles coming from left pulmonary vein to LA.**  
LA: Left atrium  
PAE: Paradoxal air embolism  
TEE: Transesophageal ecocardiography

sion was covered with bone wax in order to prevent development of further VAE.

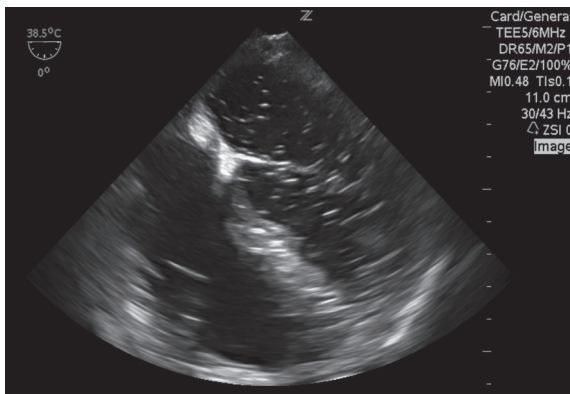
TEE images were examined after 15 minutes, and we detected a significant passage of air bubbles into the left heart. With every heart beat, air bubbles which passed through the left pulmonary vein into the left atrium were observed. In blood gas sample obtained at T3, persistence of hypoxia was observed even though 100 % oxygen (PaO<sub>2</sub>: 63.9 mmHg, PaCO<sub>2</sub>:78 mmHg) was administered. Approximately 300 mL air was aspirated through the central catheter. Hypoxic state of the blood gas (T4) sample which was obtained 30 min. later improved, and partial hemodynamic improvement was provided with noradrenalin (TA:96/53, HR:128 bpm). When passage of air into the left heart was blocked, duraplasty was performed rapidly and the operation was terminated.



**Figure 3. The long axis TEE view after PAE. Bubble airts in left cardio and aorta.**  
PAE: Paradoxal air embolism  
TEE: Transesophageal ecocardiography

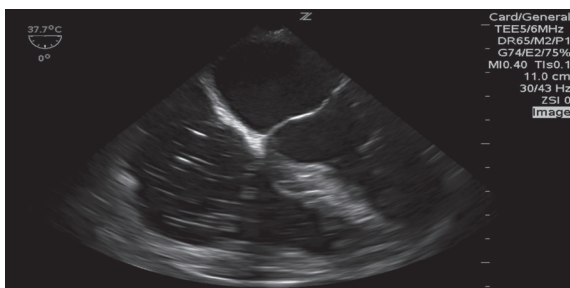TEEs were performed by two different attending cardiac anesthesiologists, both of whom verified that the air bubbles were coming from the left pulmonary vein. Postoperatively, sedated and intubated patient was transferred into the intensive care unit (ICU) for further investigations and mechanical ventilation support. On arrival in the ICU, the GCS score was 3 and the patient's pupils were equal and sluggishly reactive to light. Although hypoxia of arterial blood gas (T5) improved, state of mixed acidosis persisted. There was no signs of bleeding or edema on the control cranial CT of the patient who was partially hemodynamically stabilized with noradrenaline (0.05 µg kg<sup>-1</sup>/min) infusion. Written informed consent was obtained from the patients relatives who participated in this case report.

One day after the operation, the patient was reevaluated at the ICU by a team experienced in TEE. Ten mL of agitated (bubbled) gelatine solution was injected through a central venous catheter into the right atrium after airway pressure of 25 cm H<sub>2</sub>O was maintained for 5 sec at the end of inspiration. The fate of the injected bolus was followed throughout the ventilatory cycle, especially at the early expiration and systole periods. Air bubbles passing towards the right heart were observed, while air bubbles travelling towards the left heart were not seen (Figure 6). On the 3. postoperative day, patient died due to heart failure and ARDS in the intensive care unit.



**Figure 5. The four chamber TEE view. Common air bubbles in left heart.**

TEE: Transesophageal ecocardiography



**Figure 6. The four chamber TEE view in ICU. Agitated saline bubbles in right heart.**

ICU: Intensive care unit

TEE: Transesophageal ecocardiography

## DISCUSSION

Although sitting position which is used during posterior fossa, hypophysis and upper cervical lesion surgeries has many advantages, it causes some serious complications like venous air embolism (VAE) and its potentially fatal complication, namely paradoxical air embolism (PAE) [2,3]. Air aspiration caused by the negative pressure in the cranial veins during

the surgery while the patient is sitting may lead to catastrophic, pulmonary and neurological disabilities independent of the presence of PFO. It has been reported in many studies that the incidence of VAE in the sitting position ranged between 1, and 76 percent. In general population, PFO frequency is as high as %10-30 [3,4]. While many neurosurgeons consider sitting position contraindicated in the presence of PFO, some prefer to use the advantages of the sitting position because they claim that PAE is rarely seen even in the presence of VAE exist and that most of cases are subclinical [3,4]. For the surgeries performed while the patient is in sitting position, in order to eliminate PFO in particular, many centers use transesophageal echocardiography (TEE) as one of the routine part of the monitoring process [2-5]. It has been revealed that keeping end-inspiratory pressure high for a while in ventilator is more efficient than Valsalva maneuver in awake patient during scanning for PFO [6]. In our clinic, sitting position is routinely used especially in posterior fossa surgery too and in these cases, continuous TEE monitoring is applied for potential intraoperative development of VAE.

While small air bubbles passing through pulmonary artery are mostly absorbed in the pulmonary capillary bed without causing hemodynamic instability, sudden and massive air embolism can obstruct the pulmonary artery and right cardiac valve exit.

In this case report, we also aimed to investigate the possible mechanisms of the massive intrapulmonary right-left paradoxical air embolism which occurs during operations while the patient was maintained in the sitting position.

In surgeries performed while in the sitting position, in order to reveal the possible risks, it is extremely important to eliminate intracardiac shunting with a careful examination before the operation. Without intracardiac shunting, paradoxical air embolism occurs rarely and only a few isolated cases have been reported [7-9]. In the first case, trigeminal rhizotomy operation was being performed while the patient was in the sitting position. In the second case central venous catheter was applied, and in the last case paradoxical air embolism developed when VAE occurred while the patient was turned from sitting to supine position.



It must be emphasized that air embolism has the potential of passing from intrapulmonary arteriovenous anastomoses through the pulmonary capillary bed without being filtered. Development of PAE can be explained by means of two mechanisms: Air embolus either passes through lung capillary bed or through IPAV anastomosis which bypass this capillary bed [7].

A study in dogs suggests that when blood flow and the pulmonary resistance increase with norepinephrine, IPAV anastomosis increases vein diameter and accordingly blood flow by functioning like “pop-up valves” in order to protect the lungs against the harmful effects of the high perfusion pressures [10]. It is stated that this mechanism can be activated under conditions which increase vascular resistance like PAE which can explain the mechanism of paradoxical embolism [7].

Another mechanism is based on the theory that hypoxia eases the passing of the microbubbles by opening intrapulmonary veins. In their experimental study, Lovering et al. [1] showed that IPAV shunt increases in each subject if it is accompanied by hypoxia during the exercise. The same researchers showed that providing high FiO<sub>2</sub> is useful to decrease the occurrence of shunting.

Based on our TEE findings and blood gas analyses, we explained the PAE entity which occurs in our case without cardiac defect and results in mortal outcomes with hypoxia triggering IPAV shunt pathway activation.

## CONCLUSION

Surgeries performed while the patient is in the sitting position have higher incidence of VAE It should kept in mind that even if there is no intracardiac defect mortal PAE can occur and in these cases TEE monitoring must be performed as an obligatory and routine monitoring application.

**Informed Consent:** Written informed consent was obtained from the patients’ relatives who participated in this case report.

**Financial Disclosure:** The authors declared that they hadn’t received any sort of financial support.

**Conflict of Interest:** No conflict of interest was declared by the authors.

## REFERENCES

1. **Lovering AT, Romer LM, Haverkamp HC, Pegelow DF, Hokanson JS, Eldridge MW.** Intrapulmonary shunting and pulmonary gas exchange during normoxic and hypoxic exercise in healthy humans. *J Appl Physiol* 2008;104:1418-25.  
<http://dx.doi.org/10.1152/jappphysiol.00208.2007>
2. **Mirski MA, Lele AV, Fitzsimmons L, Toung TJ.** Diagnosis and treatment of vascular air embolism. *Anesthesiology* 2007;106:164-77.  
<http://dx.doi.org/10.1097/0000542-200701000-00026>
3. **Girard F, Ruel M, McKenty S, Boudreault D, Todorov A, Molina-Negro P, et al.** Incidences of venous air embolism and patent foramen ovale among patients undergoing selective peripheral denervation in the sitting position. *Neurosurgery* 2003;53:316-9, discussion 9-20.  
<http://dx.doi.org/10.1227/01.NEU.0000073529.40402.4E>
4. **Leonard IE, Cunningham AJ.** The sitting position in neurosurgery- not yet obsolete! *Br J Anaesth* 2002;88:1-3.  
<http://dx.doi.org/10.1093/bja/88.1.1>
5. **Kwapisz MM, Deinsberger W, Muller M, et al.** Transesophageal echocardiography as a guide for patient positioning before neurosurgical procedures in semi-sitting position. *J Neurosurg Anesthesiol* 2004;16:277-81.  
<http://dx.doi.org/10.1097/00008506-200410000-00003>
6. **Greim CA, Trautner H, Krämer K, Zimmermann P, Apfel CC, Roewer N.** The detection of interatrial flow patency in awake and anesthetized patients: a comparative study using transnasal transesophageal echocardiography. *Anesth Analg* 2001;92(5):1111-6.  
<http://dx.doi.org/10.1097/0000539-200105000-00006>
7. **Schlundt J, Tzanova I, Werner C.** A case of intrapulmonary transmission of air while transitioning a patient from a sitting to a supine position after venous air embolism during a craniotomy. *Can J Anaesth* 2012;59(5):478-82.  
<http://dx.doi.org/10.1007/s12630-012-9680-1>
8. **Black M, Calvin J, Chan KL, Walley VM.** Paradoxical air embolism in the absence of an intracardiac defect. *Chest* 1991;99:754-5.  
<http://dx.doi.org/10.1378/chest.99.3.754>
9. **Marquez J, Sladen A, Gendell H, Boehnke M, Mendelow H.** Paradoxical cerebral air embolism without an intracardiac septal defect. Case report. *J Neurosurg* 1981;55:997-1000.  
<http://dx.doi.org/10.3171/jns.1981.55.6.0997>
10. **Berk JL, Hagen JF, Tong RK, Levy ML, Martin PJ.** The role of adrenergic stimulation in the pathogenesis of pulmonary insufficiency. *Surgery* 1977;82:366-72.